

## **In vivo experimental model for the evaluation of dental implant integration**

Received for publication, November, 3, 2017  
Accepted, December, 27, 2017

**ALEXANDRU POLL<sup>1</sup>, VANDA ROXANA NIMIGEAN<sup>2</sup>, DANIELA BĂDIȚĂ<sup>3</sup>,  
ROSALIE ADINA BĂLĂCEANU<sup>4</sup>, SUZANA CARMEN CISMAS<sup>5</sup>,  
PAULA PERLEA<sup>6</sup>, SIMONA ANDREEA MORARU<sup>2</sup>, VICTOR NIMIGEAN<sup>1</sup>**

<sup>1</sup>Anatomy Department, Faculty of Dental Medicine, "Carol Davila" University of Medicine and Pharmacy, Bucharest, Romania; <sup>2</sup>Oral Rehabilitation Department, Faculty of Dental Medicine, "Carol Davila" University of Medicine and Pharmacy, Bucharest, Romania; <sup>3</sup>Physiology Department, Faculty of Dental Medicine, "Carol Davila" University of Medicine and Pharmacy, Bucharest, Romania; <sup>4</sup>Physiology Department, Faculty of Veterinary Medicine, University of Agronomical Sciences and Veterinary Medicine, Bucharest, Romania; <sup>5</sup>English Teaching Discipline the Faculty of Management, Economics Engineering and Rural Development, University of Agronomical Sciences and Veterinary Medicine, Bucharest, Romania; <sup>6</sup>Department of Endodontics, Faculty of Dental Medicine, "Carol Davila" University of Medicine and Pharmacy, Bucharest, Romania.

**Corresponding author:** Vanda Roxana Nimigean, Associate Professor, Head of Oral Rehabilitation Department, Faculty of Dental Medicine, "Carol Davila" University of Medicine and Pharmacy, Bucharest, Romania, No 17-23 Calea Plevnei Street.  
Phone: +40721561848. E-mail: vandanimigean@yahoo.com

### **Abstract**

*The present report details the insertion of a dental implant, subsequent to bone augmentation, in a medium-sized dog (15.4 kg), of common breed (Canis Familiaris), which showed a dento-alveolar trauma at the level of the right maxillary second premolar. The implemented treatment is presented, and the healing process has been discussed taking into account opinions presented in specialised literature.*

*Dental implant treatment in association with a guided bone regeneration protocol was recommended to preserve the local morphology. The evolution was favourable after surgery. A one year follow-up period with monthly clinical and radiographic evaluation was considered. This therapeutic approach yielded good results.*

*The report therewith evaluates biomaterials (bone autograft and bone xenograft) used for dental implants integration and dental implants sites augmentation, in accordance with the legislation for the protection of animals used for scientific purposes.*

*This research suggests an in vivo experimental model for the assessment of clinical success in implant dentistry, not entailing the euthanasia of the specimen used, in accordance with the Directive 2010/63/EU.*

**Keywords:** alveolar process defect, bone graft, biomaterial, dental implant

### **Introduction**

Recent scientific advances in the field of implant dentistry have enabled the development of new biotechnologies, especially bone regeneration techniques using biomaterials.

A maxillary or mandibular dento-alveolar trauma, with corono-radicular fractures and fractures of the alveolar compact, may result in a certain bone defect after dental extraction and the removal of alveolar fragments, which requires alveolar reconstruction with bone grafts, and, after healing, a dental implant and a crown.

The aim of this study was to describe the clinical management of a dento-alveolar traumatic defect occurring in the upper right second premolar of a common breed (*Canis Familiaris*) medium-sized dog (15.4 kg), and to show that implant-prosthetic treatment can be a therapeutic alternative for pets of medium or large sizes.

This experimental model is useful for the assessment of bioactive capacity of the maxillary alveolar bone.

## Material and methods

The specimen was brought to the Surgical Emergency Department of the Faculty of Veterinary Medicine, in Bucharest Romania, by its owner, who stated that the dog had suffered an aggression, consequently showing slight gum bleeding and avoiding food ingestion.

For easy and non-traumatic examination, the sedation of the animal was decided upon.

The anesthetic protocol consisted of premedication with acepromazine administered by intramuscular injection (0.012 mg/bodyweight), followed by ketamine administration, also by intramuscular injection (0.015 mg/bodyweight). This technique of general anesthesia lasts about 1.5 hours.

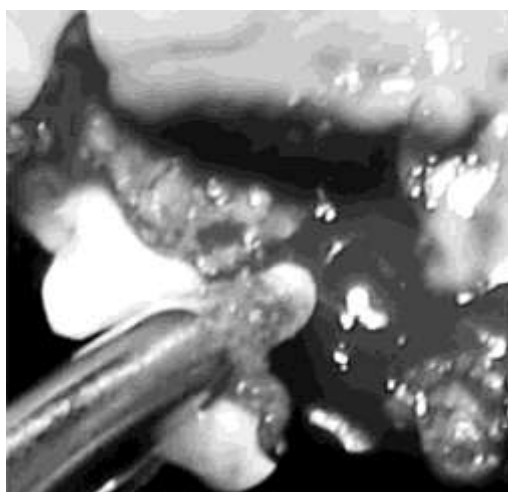
Intra-oral examination revealed high mobility of the upper right second premolar, mild inflammation of the adjacent mucosa, and slight bleeding in the free gingival margin.

The clinical diagnosis was dento-alveolar fracture.

Dental implant treatment in association with a guided bone regeneration protocol was recommended to preserve the local morphology.

## Results and discussions

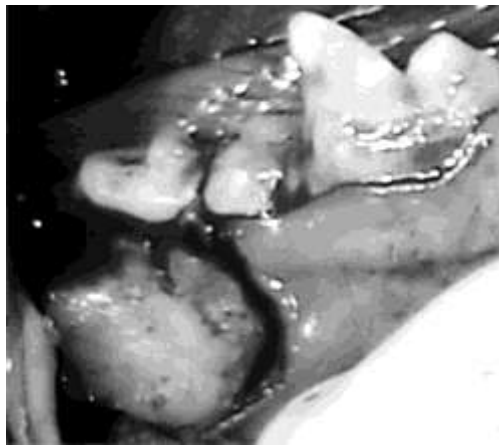
Firstly, the affected region was swabbed with a solution of 2% chlorhexidine digluconate, and the loose dental segment, as well as a portion of the alveolar process, were removed (Figure 1). Then, the fractured dental root of the right maxillary second premolar was extracted through an open extraction technique. Using a continually cooled bone drill running at a low speed, the edges of the bone defect were smoothed post-extraction. The extraction technique was customised to the dento-alveolar morphology.



**Figure 1.** Tooth extraction.

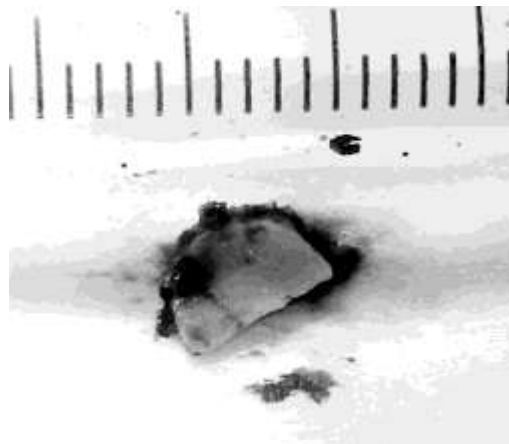
The resulting post-extraction alveolar defect was then augmented with a corticocancellous mandibular graft. The graft was collected from the posterior buccal region (Figure 2), as this is the level where the mandible in dogs is thickest, and the mandibular

canal is farthest, with an average of 3-3.5 mm, radiographically measured, the mandibular canal being closer to the medial (lingual) cortical bone plate, similar to that of the human species (V. NIMIGEAN [1], C.E. GEORGESCU & al. [2]).



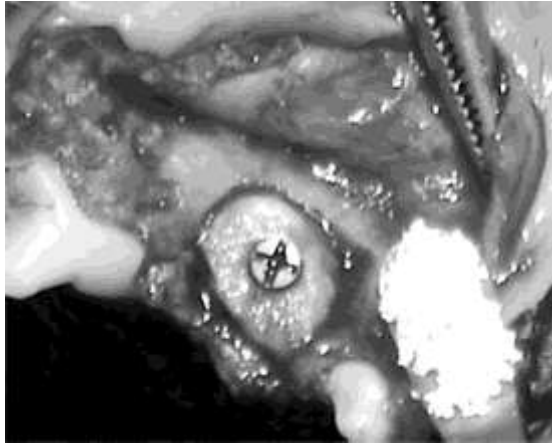
**Figure 2.** Bone sampling.

The mandibular bone graft was isolated using continually cooled bone drills running at low speed, and was then collected using surgical chisels (Figure 3). The mandibular bone defect was filled with Bio-Oss (Geistlich), covered with a Bio-Guide 13x25 mm (Geistlich) absorbable membrane, and the muco-gingival tissues were sutured with non-absorbable number 3.0 silk thread.

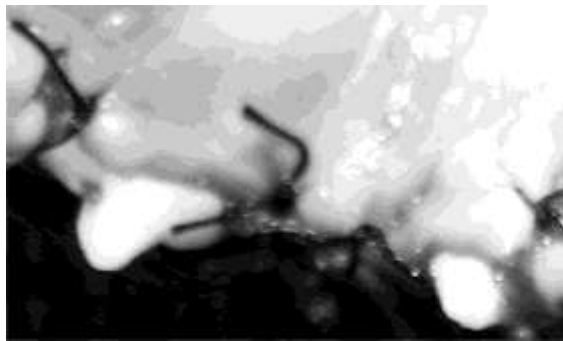


**Figure 3.** The harvested mandibular bone graft.

Afterwards, the mandibular bone graft was modified to fit the maxillary alveolar defect, and then, with a pilot drill, a hole was made in the graft so as to insert the titanium fixation screw, that was 6 mm long and had a diameter of 1 mm. Only one fixation screw was used, as the mandibular graft applied to the maxilla was highly stable. Bio-Oss (Geistlich) biomaterials xenografts were applied, additionally, at the interface, and the soft tissues were sutured with non-absorbable, number 3.0 silk thread (Figures 4, 5). Maximum preservation of the keratinized mucosa was envisaged and accomplished.

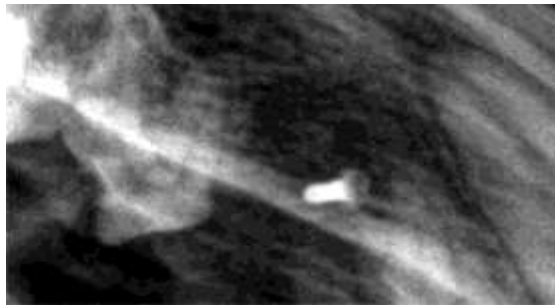


**Figure 4.** Mandibular graft (biomaterial) fixated and adapted to the maxillary alveolar defect. Bio-Oss was applied to the interface (biomaterial).



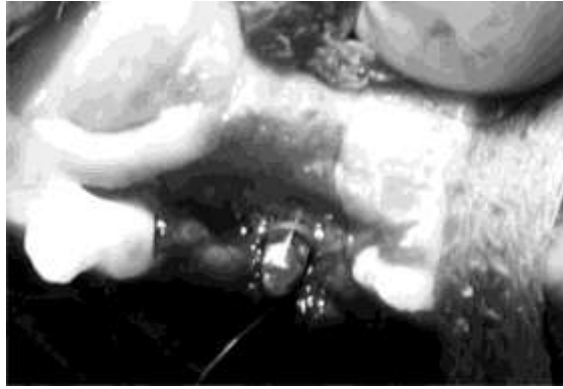**Figure 5.** The graft, completely covered by sutured soft tissues.

The dog consumed soft food for 90 days following the surgical procedure. The post-surgical evolution was favourable, with no local or general complications. Following the surgery, a treatment of anti-inflammatory analgesics was used, 500 mg for 24 hours, over 5 days, and the sutures were removed after 12 days. Subsequent healing was monitored both clinically and through the use of X-rays (Figure 6).

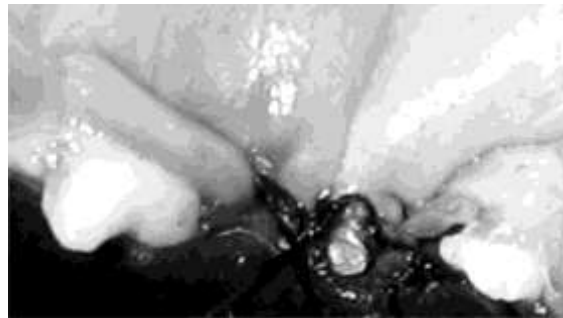

**Figure 6.** Follow-up X-ray.

The mucosa was completely healed 4 months after the surgical intervention, the region showed correct morphology, and bone resorption following grafting, noticeable via X-ray, was low. The fixation screw was afterwards removed from the graft and a personally devised stage I dental implant was inserted (Figure 7). The dental implant was conceived after the completing of radiographic and morphometric studies in the lateral maxillary region of the medium size, common breed dog (V. NIMIGEAN [1]). The soft tissues were sutured with non-absorbable, number 3 silk threads (Figure 8).

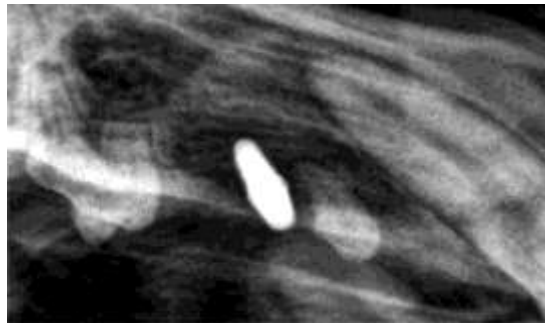


**Figure 7.** Insertion of the dental implant.

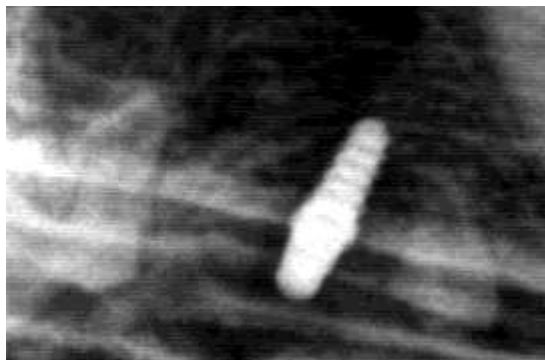


**Figure 8.** The abutment segment of the implant and the suture of the wound.

Immediately after insertion, the dental implant showed very good primary stability. The post-surgical evolution was favourable, with no local complications, the only treatment applied was for pain management, 500 mg for 24 hours, during 3 days, and the stitches were removed after 10 days. Epithelial tissue, connective tissue and bone integration follow-up was monthly, both clinically and radiographically (Figures 9, 10).

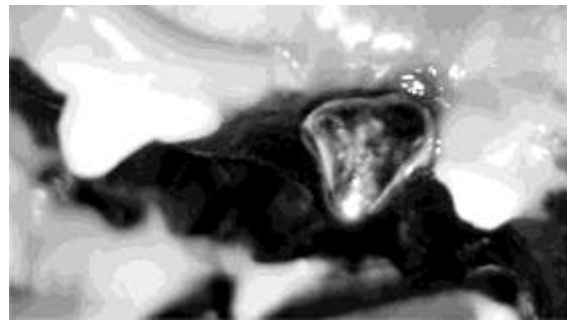


**Figure 9.** Immediate check-up X-ray.



**Figure 10.** Follow-up X-ray, 3 months after implant surgery.

92 days after the insertion, the dental implant was loaded using a nickel-chromium crown, cast on the basis of a previous polyether-based impression (Figure 11). In the following year bimonthly check-ups were performed.



**Figure 11.** The cast crown in place.

5 months after the application of the crown, the evolution towards mixed, soft food, was good, without complications or changes to be noticed. Care continued in the following months.

Both during and after the surgical interventions, H.L. MYSHIN and J.P. WIENS's [3], observation regarding soft tissues was taken into account, namely "a healthy gingival mucosa is critical for the success of the treatment".

The attempt was to maintain as extensive width of the keratinized mucosa as possible, so as to minimise bone resorption and create a stable peri-implant soft tissue attachment.

For clinical evaluation of peri-implant soft tissues healing, traditional periodontal parameters were applied (M. QUIRYNEN & al. [4]).

We considered that the mandibular bone graft used in this case represents the maximum standard, due to the same embryological development with the maxilla, even though specialised literature shows that mandibular graft resorption takes place at a quite high rate, 41.5% (L. CORDARO & al. [5]). Regarding the ideal graft, there are also controversies in literature, and so R.B. BELL & al. [6], show a lesser resorption rate, of 32%, in the case of iliac bone auto-grafts, despite the fact that it has a different embryological development as compared to the mandible and the maxilla. G. WIDMARK & al. [7], show that mandibular auto-grafts can be used on people with a narrow alveolar crest, even if the resorption of the graft could be expanded.

In order to quantify bone graft success, graft stability was taken into account, as well as complete soft tissue coverage and re-establishment of vascularisation, aspects that were also considered by other authors (A. SETHI and T. KAUS [8]). Regarding the embryological origin of bone auto-grafts, since 1983, J.E. ZINS and L.A. WHITAKER [9], have demonstrated that the common embryological origin of the donor region and the recipient region represents an important criterion for success. F. SANTORO & al. [10], proved that use of mandibular auto-grafts is the recommended method to solve different types of alveolar resorption. In the case of mandibular grafts used for the reconstruction of the maxillary alveolar region, S.M. BALAJI [11], reports a success rate of 81.2%. Also, F. HERNANDEZ-ALFARO & al. [12], showed that use of mandibular grafts combined with biomaterials is an adequate procedure for rehabilitation of the severely resorbed maxilla.

P.J. LOUIS [13], argues that even if autogenous grafts implementation was the golden standard in the past, recent studies have shown that vertical or horizontal augmentation can be successful in the case of allogenic or xenogenic grafts covered by membranes, and that the use of growth factors would enhance success rates consistently.

Insufficient sanguine flow in the bone or in the surrounding soft tissue, as well as variations in local vascularisation, can negatively influence healing, resulting in delayed fusions, or non-fusions, between donor and receiving elements (A. ORYAN & al. [14]).

Other authors also pointed out that angiogenesis in grafting areas, through the presence of capillary veins, along with reduced local inflammation, increases with the abundance of the inflammatory infiltration (A. BUNGET & al. [15]).

In order to avoid certain accidents or complications, it was taken into account that the trajectory of the mandibular canal in the posterior region of the mandible, for the human species, shows topographic characteristics similar to those of the canine species, more specifically, it is closer to the medial (lingual) cortical bone plate (D.J. LEONG & al. [16]).

For long term success, it has been considered that implant loading influences bone tissue formation through increased vascularisation and metabolism, resulting in bone remodelling, as new bone grows at interface under the pressure of loading, not in its absence; the type of restorative implant prosthesis plays an important role (D. BOTTICELLI & al. [17], R.A. LEVINE [18], G.E. ROMANOS & al. [19]).

This research suggests an *in vivo* experimental model for the assessment of clinical success in implant dentistry, not entailing the euthanasia of the specimen used, in accordance with the Directive 2010/63/EU.

## **Conclusions**

The therapeutic approach yielded good results.

This clinical case evolution has shown that mandibular auto-grafts in combination with bone xenografts are biomaterials with favourable outcomes in bone regeneration and implant osseointegration. The posterior mandibular region represents an adequate alternative for the resizing of maxillary alveolar crests with volume deficiencies.

The report highlights that the canine may be considered a suitable *in vivo* experimental model for the assessment of biomaterials used in bone tissue regeneration; the study is in accordance with the three principles “Reduction, Refinement and Replacement” of the Directive 2010/63/EU.

## **Conflict of interests**

The authors declare that they have no conflict of interests.

## **Acknowledgments**

Part of the research for this case report was conducted within Alexandru Poll’s PhD Thesis, “Fundamental studies regarding biocompatibility of grafts used to augment maxillary and mandibular bone volume”.

The stipulations in the European Council’s Directive 86/609/EEC and Directive 2010/63/EU, for the protection of animals used for scientific purposes, were complied with. Also, the study was endorsed by the Ethics Committee of the Faculty of Veterinary Medicine in Bucharest and the study was in accordance with local laws and regulations.

## **Author contribution**

Author #1 (Alexandru Poll), autor #3 (Daniela Bădiță), autor #4 Rosalie Adina Bălăceanu, autor #6 (Paula Perlea), autor #7 (Simona Andreea Moraru) and autor #8 (Victor Nimigean) have equal contributions to this paper and thus are main authors.

## **References**

1. V. NIMIGEAN, *Studii privind integrarea osoasă și epitelio-conjunctivă a implanturilor dentare (Studies regarding bone and soft tissues integration to dental implants)*. Ed. Tehnoplast Company S.R.L., București, 2011, pp. 34-35, 193-206.
2. C.E. GEORGESCU, A. MIHAI, A.C. DIDILESCU, R. MORARU, V. NIMIGEAN, V.R. NIMIGEAN, G. TĂNASE, *Cone beam computed tomography as a method of quantitative and qualitative analysis of alveolar crest in the frontal mandibular area*. Rom. J. Morphol. Embryol., 51(4), 713-717 (2010).
3. H.L. MYSHIN, J.P. WIENS, *Factors affecting soft tissue around dental implants: A review of the literature*. J. Prosthet. Dent., 94(5), 440-444 (2005).
4. M. QUIRYNEN, D. VAN STEEBERGHE, R. JACOBS, A. SCHOTTE, P. DARIUS, *The reliability of pocket probing around screw-type implants*. Clin. Oral Implants Res., 2, 186-192 (1991).
5. L. CORDARO, D.S. AMADE, M. CORDARO, *Clinical results of alveolar ridge augmentation with mandibular block bone grafts in partially edentulous patients prior to implant placement*. Clin. Oral Implants Res., 13, 103-111 (2002).
6. R.B. BELL, G.H. BLAKEY, R.P. WHITE, D.G. HILLEBRAND, A. MOLINA, *Staged reconstruction of the severely atrophic mandible with autogenous bone graft and endosteal implants*. JOMS, 60, 1135-1141 (2002).
7. G. WIDMARK, B. ANDERSSON, C.J. IVANOFF, *Mandibular bone graft in the anterior maxilla for single-tooth implants. Presentation of surgical method*. Int. J. Oral Maxillofac. Surg., 26(2), 106-109 (1997).
8. A. SETHI, T. KAUS, *Practical Implant Dentistry: Diagnostic, Surgical, Restorative and Technical Aspects of Aesthetic and Functional Harmony*. Quintessence Publishing, 2005, pp. 176.
9. J.E. ZINS, L.A. WHITAKER, *Membranous versus endochondral bone: implications for craniofacial reconstruction*. Plast. Reconstr. Surg., 76, 510-516 (1983).
10. F. SANTORO, C. MAIORANA, M. RABAGLIATI, *Long-term results with autogenous onlay grafts in maxillary and mandibular atrophy*. J. Long Term Eff. Med. Implants, 9(3), 215-222 (1999).
11. S.M. BALAJI, *Management of deficient anterior maxillary alveolus with mandibular parasymphiseal bone graft for implants*. Implant Dent., 11(4), 363-369 (2002).
12. F. HERNÁNDEZ-ALFARO, M. SANCHO-PUCHADES, GUIJARRO- R. MARTÍNEZ, *Total Reconstruction of the Atrophic Maxilla with Intraoral Bone Grafts and Biomaterials: A Prospective Clinical Study with Cone Beam Computed Tomography Validation*. Int. J. Oral Maxillofac. Implants, 28, 241-251 (2013).
13. P.J. LOUIS, *Bone Grafting the Mandible*. Oral Maxillofacial. Surg. Clin. N. Am., 23, 209-227 (2011).
14. A. ORYAN, S. ALIDADI, A. MOSHIRI, N. MAFFULLI, *Bone regenerative medicine: classic options, novel strategies, and future directions*. J. Orthopaedic Surg. Res., 9(1), 18 (2014).
15. A. BUNGET, A. FRONIE, E. AFREM, D. CORLAN PUSCU, H. MANOLEA, A.R. DAN, M. COMAN, V.R. NIMIGEAN, *Microscopic aspects of angiogenesis and lymphangiogenesis in oral squamous cell carcinoma*. Rom. J. Morphol. Embryol., 54(3), 623-627 (2013).
16. D.J. LEONG, J. LI, I. MORENO, H.L. WANG, *Distance between external cortical bone and mandibular canal for harvesting ramus graft: a human cadaver study*. J. Periodontol., 81(2), 239-243 (2010).
17. D. BOTTICELLI, L.G. PERSSON, J. LINDHE, T. BERGLUNDH, *Bone tissue formation adjacent to implants placed in fresh extraction sockets: an experimental study in dogs*. Clin. Oral Implants Res., 17(4), 351-358 (2006).
18. R.A. LEVINE, *Soft Tissue Considerations for Optimizing Implant Esthetics*. Functional Esthetics & Restorative Dentistry, 2, 54-62 (2007).
19. G.E. ROMANOS, C.G. TOH, C.H. SIAR, H. WICHT, H. YACOB, G.H. NENTWIG, *Bone-Implant Interface Around Titanium Implants Under Different Loading Conditions: A Histomorphometrical Analysis in the Maccaca fascicularis Monkey*. J. Periodontol., 10, 1483-1490 (2003).